



Impact of Body Weight, Height, and Obesity on Selection of Skin Entry Point for Transforaminal Endoscopic Lumbar Discectomy

Prasad Patgaonkar¹ Vaibhav Goyal¹ Utkarsh Agrawal¹ Nandan Marathe¹ Vivek Patel¹

¹Department of Orthopaedic-Spine, Indore Spine Centre, Indore, Madhya Pradesh, India

Address for correspondence Vaibhav Goyal, MBBS, DNB (Ortho), Indore Spine Centre, 126, LIG Link Road, Anoop Nagar, Indore, Madhya Pradesh 452009, India (e-mail: vgvoyal1@gmail.com).

AJNS

Abstract

Background Prospective evaluation of the effect of physical parameters like height, weight and abdominal girth on different skin entry points in transforaminal endoscopic lumbar discectomy (TELD) in lower lumbar discs.

Methods This prospective study involved 174 patients with unilateral radicular pain or discogenic back pain, central, paracentral disc herniations and lateral canal stenosis at the level from L3 to S1 radiologically confirmed by magnetic resonance imaging (MRI) and failed conservative trial for 6 weeks. All patients underwent measurements of height, weight, body mass index (BMI), and abdominal girth preoperatively. All the four possible entry points, i.e., 45 to 45, posterolateral (PL), tip of spinous process (TOSP), and dorsum of the facet joint, were marked and point midway between PL and TOSP (PL-TOSP) skin entry was used.

Results The change in the value, i.e., distance from midline of all the entry points with physical parameters like height, weight, BMI, and abdominal circumference was statistically significant. The visual analog scale score decreased from a preoperative value of 7.98 to 1.84 at 6 months follow-up. The Oswestry disability index score improved from 72.53 to 16.26.

Conclusion The entry point in TELD is not a fixed value as it varies with the physical parameters like weight and abdominal girth of the patient. PL-TOSP is a safe entry point for common pathologies like central, paracentral herniations and lateral canal stenosis in lower lumbar levels and can be predicted preoperatively by proposed formula.

Keywords

- ▶ TELD
- ▶ PL-TOSP
- ▶ lumbar disc herniation
- ▶ endoscopy

Introduction

Transforaminal endoscopic lumbar discectomy (TELD) has evolved by leaps and bounds in the past decade. Endoscope design, instrumentation, and surgical techniques have improved vastly in recent times. The knowledge of endoscopy

visually visualizing and treating painful pathologies through the transforaminal approach has created the space for diagnosis and treatment of disc pathologies and degenerative lumbar spine conditions in a true minimally invasive manner.¹ The unique characteristics of spinal working channel endoscope differentiate the endoscopic spine surgery from other

DOI <https://doi.org/10.1055/s-0042-1751005>.
ISSN 2248-9614.

© 2022. Asian Congress of Neurological Surgeons. All rights reserved.

This is an open access article published by Thieme under the terms of the Creative Commons Attribution-NonDerivative-NonCommercial-License, permitting copying and reproduction so long as the original work is given appropriate credit. Contents may not be used for commercial purposes, or adapted, remixed, transformed or built upon. (<https://creativecommons.org/licenses/by-nc-nd/4.0/>)

Thieme Medical and Scientific Publishers Pvt. Ltd., A-12, 2nd Floor, Sector 2, Noida-201301 UP, India

minimally invasive spine surgeries. The principles of minimally invasive spinal techniques are further promoted by spinal endoscope as the surgeon can visualize the spinal contents in an expanded angle field of view (20–90 degrees), which is far better compared with the microscope vision.

In 1972, Kambin introduced a posterolateral (PL) approach for endoscopic discectomy by defining the Kambin's triangle. The proposed Kambin's triangle is the "safe zone" to approach the intervertebral disc as this approach protects the epidural and neural structures, thus prevents chronic nerve edema, epidural bleeding, and scarring. It is defined as a triangle over the dorsolateral disc with hypotenuse as the exiting nerve root, the base is the superior border of the caudal vertebra, and the height is the dura/traversing nerve root.^{2–4}

Since then, technological advancements have given surgeons the ability to safely approach the disc through a percutaneous PL transforaminal approach, endoscopically visualize the herniation, and utilize specialized instruments to remove the offending disc fragment. Further advancements in the technique occurred to better target each type of herniation and stenosis with precise needle trajectory and cannula positioning directed at the site of targeted decompression.^{5–13}

However, we need to further simplify the procedure, especially for beginners, to reduce the existing long learning curve and improve accuracy. Most of the previous studies suggesting the skin entry point for needle insertion is calculated based on preoperative magnetic resonance imaging (MRI) and computerized tomography (CT) scan by measuring the distance from midline and needle trajectory is aimed to target herniated fragment without entering peritoneal sac and to debride the facet.^{14,15} It shows dependency on preoperative imaging with the field of vision view, including the posterior abdominal wall in an axial cut. TELD can give very good to excellent results, provided adequate decompression of the targeted nerve root is achieved. The preoperative planning of TELD includes identifying the symptomatic nerve root to be decompressed, optimized skin entry point selection, needle trajectory, and docking of the needle on the SAP or annulus during outside-in or inside-out technique, respectively.¹⁶

This study was planned to determine whether physical parameters including body weight, height or abdominal girth of a patient can affect the point of entry for TELD. We also aim to determine whether any of these entry point distance can be derived preoperatively for individual patient based on variations in physical parameters.

Materials and Methods

Patients and Study Design

This prospective observational study of 174 surgical cases performed by a single surgeon was conducted at a tertiary care spine center. The study was commenced after approval from the institutional review board. The study duration was from June 2017 to June 2019. There were 91 males and 83 females in the study. The patients were evaluated preopera-

tively and postoperatively up to 6 months using the visual analogue scale (VAS) and Oswestry Disability Index (ODI). The preoperative neurological status was determined. All the patients underwent dynamic X-rays of the lumbar spine (flexion and extension views) to rule out segmental instability. All the patients underwent measurements of height, weight, and abdominal girth preoperatively. Body mass index (BMI) was calculated in all patients. All patients underwent TELD under monitored care anesthesia and local anesthesia with 1% preservative-free lidocaine in prone position under image intensifier control. Patients with unilateral radicular pain or discogenic back pain, central paracentral disc herniations and lateral canal stenosis at the level from L3 to S1 proven by MRI corresponding to the neurological findings, positive nerve root tension sign and or positive neurological finding in terms corresponding dermatomal numbness or weakness, with a failed conservative trial for a duration of 6 weeks were included in the study. Patients with foraminal and extraforaminal herniations, central canal stenosis with significant ligamentum flavum hypertrophy, spondylolisthesis with instability, and those lost to follow-up were excluded from the study.

Surgical Steps

1. All the procedures were performed under local anesthesia and monitored anesthesia care on the radiolucent operating table in a prone position using horizontal bolsters.
2. We used the YESS geometrical technique of drawing PL and 45 to 45 entry points.¹⁷ We also marked the tip of spinous process (TOSP) and dorsum of the facet joint (DFJ) on the lateral fluoroscopic image to get the far lateral entry points. We marked all four entry points in every patient. We always measure our fifth entry point as midway between PL-TOSP (→Figs. 1 and 2).
3. PL-TOSP entry was used as our preferred entry point in all the cases.
4. An 18-gauge 20-cm puncture needle is used under fluoroscopic guidance to target the pathology through the Kambin's triangle so that it avoids injury to the exiting nerve root and enters the annulus very close to the targeted site of decompression by inside-out or outside-in technique of TELD. We used Maxmore GmbH sequential reamers for the outside-in technique.
5. A guidewire is placed through the needle once the needle placement is confirmed under fluoroscopic guidance in antero-posterior and lateral views. Then dilator and the outer sheath are inserted with care to avoid exiting nerve root injury. The patient is asked for any increased leg pain, numbness, or weakness of ankle dorsiflexion, plantar flexion, and active toe movements while inserting dilator and outer sheath.
6. We used a 30-degree 18-cm shaft 3.75 mm working channel endoscope.
7. The end point of decompression was considered as the patient's confirmation of pain relief, fluttering of epidural fat from the tip of SAP to the middle of the caudal pedicle, and visualized decompression of traversing nerve root.

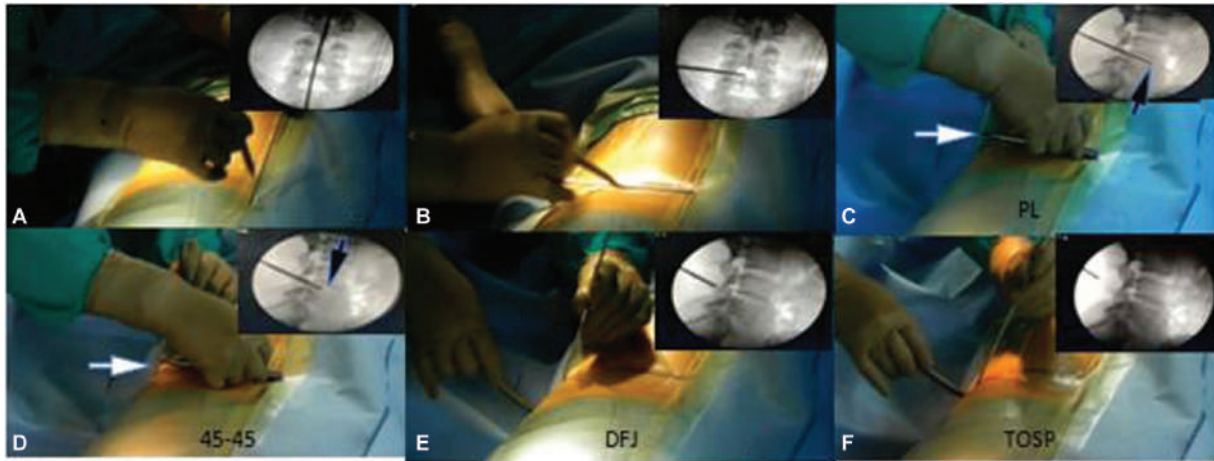


Fig. 1 Patient in prone position with surgeon standing on the left side of the patient. (A) Marking of vertical midline in anteroposterior fluoroscopic view; (B) Marking horizontal line at the level of disc on anteroposterior view; (C–F) Metal rod is placed on disc inclination line in orthogonal lateral view: (C) showing marking of PL entry by measuring the distance between dorsal surface of patient's back (white arrow) and anterior vertebral border (black arrow). Panel (D) showing marking of 45–45 entry by measuring the distance between dorsal surface of patient's back (white arrow) and middle of the disc (black arrow). The distance marked on the metal rod is then used to mark the entry point (PL and 45–45) distance from vertical midline. (E) showing marking of dorsal aspect of facet Joint line (DFJ) on lateral fluoroscopic view. (F) showing marking of tip of spinous process (TOSP) on lateral fluoroscopic view.

Statistical Analysis

Statistical analysis was performed by SPSS 23.0 version. Continuous variables were described as mean and variation of each observation from the mean value (standard deviation)

represented as mean \pm SD. An independent *t*-test was used for finding out the association between continuous variables between two groups. Categorical data were represented as frequencies and percentages. A Chi-square test was used to find out the association between the categorical

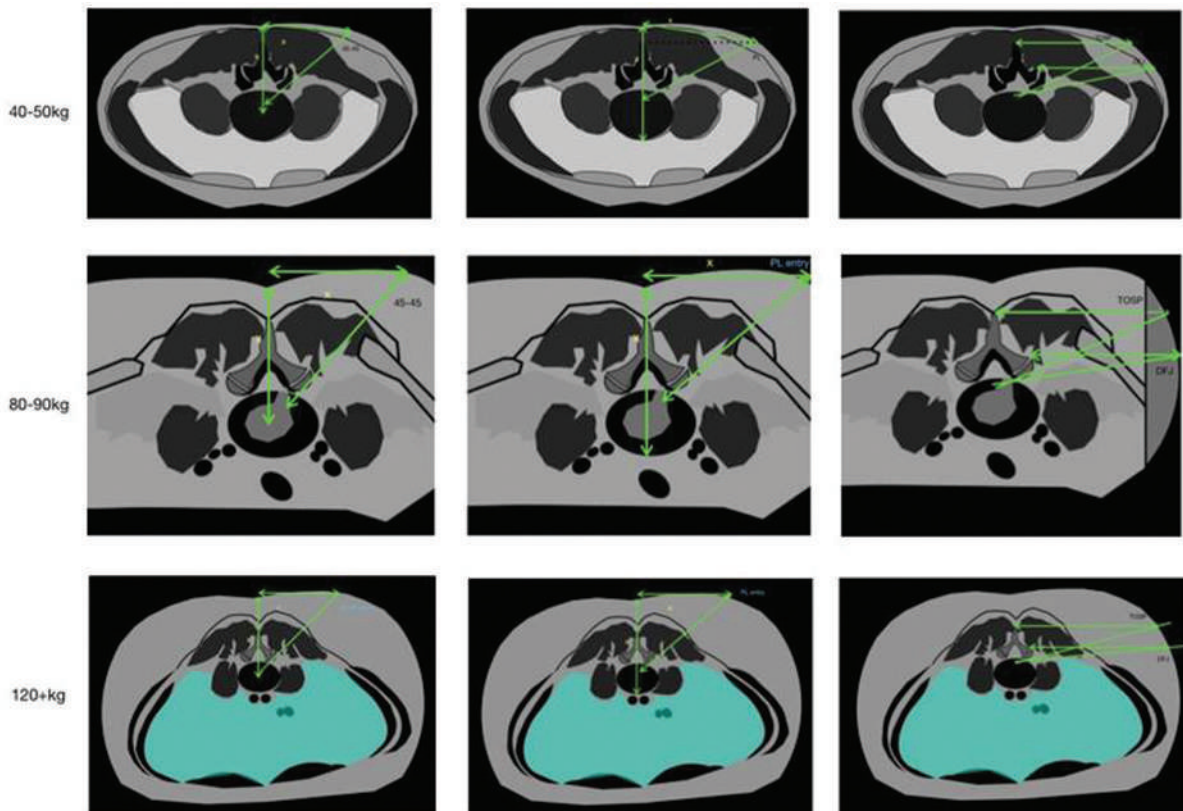


Fig. 2 Schematic diagram showing the exact method of marking the skin entry points and changes in trajectory of 45–45, PL, TOSP & DFJ entry points with physical parameters. 1st row 45 kg, 2nd row 85 kg and 3rd row 125 kg patients.

Table 1 Mean values of various parameters

Baseline variables		N = 174
Age	Mean ± SD	44.41 ± 15.13
Height		162.83 ± 11.17
Weight		69.64 ± 14.08
BMI		26.59 ± 6.55
Abdominal girth		88.41 ± 13.08
Gender number (Percentage)	Males	91 (52.3)
	Females	83 (47.7)

Note: Values are presented as mean ± standard deviation.

variables. Comparison analysis between three groups was done using the ANOVA test. Variables with p -value < 0.05 were considered as statistically significant. Correlation for PL length, TOSP, the entry point taken (PL-TOSP), and continuous variables was done using the Pearson correlation test. In contrast, the correlation for categorical variables was done using the Spearman correlation test. The prediction equation was calculated using linear regression. Cut off point for BMI was calculated using the ROC curve in patients with a positive difference for TOSP-PL length.

Results

A total of 174 patients were included in the study. The study population included 91 males and 83 females. The mean age of patients was 44.4 ± 15.13 years. Mean height and weight was 162.83 ± 11.17 cm and 69.64 ± 14.08 kg, respectively, whereas mean BMI and abdominal girth was 26.59 ± 6.55 and 88.41 ± 13.08 cm, respectively (► **Table 1**). Most common PL entry point was in range greater than 10 to 13 cm ($n = 126$) and the most common TOSP entry point was in range greater than 13 to 20 cm ($n = 142$).

The increase in the value of all five entry points, i.e., 45 to 45, PL, PL-TOSP, TOSP, and DFJ was observed with physical parameters like weight, BMI, and abdominal girth. This change was statistically significant (p -value < 0.0001). No direct or considerable change was noted with any of the five

entry points with a difference in gender, age, or height of the patient. ► **Table 2** summarizes the result.

The entry point Y (PL-TOSP) can be predicted by following the proposed formula:

$$Y = 6.88 + (0.06 \times \text{weight in kg}) + (0.024 \times \text{abdominal girth in cm})$$

where Y is the midpoint of PL-TOSP.

This formula does not apply to BMI less than 18.55.

The overall VAS score decreased from a preoperative value of 7.98 to 1.84 at 6 months' follow-up (p -value < 0.05), and the overall ODI score improved from 72.53 to 16.26 (p -value < 0.05). Complications of our study included seven recurrences (4.02%), three cases of dysesthesia (1.72%), and two revision surgery (1.14%). We did not encounter any case with a dural tear, neurological deterioration, or discitis.

Discussion

Degenerative lumbar disc disease is a common condition affecting approximately 90% of the adult population during their lifetime. Disc herniation is one of the stages of the degenerative cascade described by Kirkaldy-Willis. The surgical management for disc herniation pathologies has developed from traditional open spine surgeries to minimal access, including endoscopic spine surgeries. The development of the percutaneous endoscopic technique for lumbar spine pathologies represents an attempt to improve the operating efficacy, alleviate the postoperative pain, reduce the duration of patient's hospital stay, minimize the risk of iatrogenic instability, and minimal perineural fibrosis. Kambin and Gellmann first described the "Kambin's triangle," which is the safe zone for accessing the transforaminal region.⁹ The next significant development came when Yeung et al introduced standard transforaminal endoscopic surgery in 2002. Since then, various endoscopic minimally invasive techniques are increasingly being used to treat lumbar disc herniation. This was followed by multiple advancements in technologies and instrumentation to deal with central herniations, various types of foraminotomies for migrated herniations, transiliac approach, and surgical classification of supra iliac or transiliac approach for L5-S1 and transpedicular approach for far migrated herniations.^{8,18–22} Still, we

Table 2 Variation in entry points with various physical parameters

Physical characteristics	p -Value for 45–45 entry point	p -Value for PL entry point	p -Value for TOSP entry point	p -Value for PL-TOSP entry point	p -Value for DFJ entry point
Age	0.044	0.002	0.095	< 0.0001	0.012
Height	0.316	0.684	0.708	0.101	0.146
Weight	< 0.0001	< 0.0001	< 0.0001	< 0.0001	< 0.0001
BMI	< 0.0001	< 0.0001	< 0.0001	< 0.0001	< 0.0001
Abdominal girth	0.001	< 0.0001	< 0.0001	< 0.0001	< 0.0001

Abbreviations: DFJ, dorsum of the facet joint; PL, posterolateral; TOSP, tip of spinous process.

Note: The increase in the value of all five entry points, i.e., 45–45, PL, PL-TOSP, TOSP, and DFJ, was observed with physical parameters like weight, BMI, and abdominal girth. This change was statistically significant (p -value < 0.0001). No direct or considerable change was noted with any of four entry points with a difference in gender, age, or height of the patient.

have got challenges in the form of a long learning curve, instrumentation constraints, preoperative planning of exact entry point selection for reaching the target pathology, and high radiation exposure to the surgeon as well as the patient.

Yeung and Tsou first described the traditional entry point for TELD as the distance from the center of the disc to the plane of the posterior skin line in the line of inclination of the disc space. The length used is the same as that for the skin window perpendicular to the distance from the midline. The skin window's cephalad-caudad location is determined at the point where the disc inclination line projects from the plane of the posterior skin.^{14,15,17} Lee et al evaluated the accuracy of this proposed PL entry point on pre-operative MRI and postoperative CT scans.²³ Yeu et al,⁵ in their study of full endoscopic spine surgery, quote “the more intra-foraminal position of the scope that is needed, the closer to the posterior facet line the entry point should be for the spinal needle entry⁵.” Ahn, in their study, used the entry point between tip of the spinous process (TOSP) and spino-laminar junction.²⁴ These fixed entry points have limitations in the form of either difficulty in reaching the site of pathology or high chances of exiting nerve root injury and bowel injury with the more horizontal and far lateral ones.

We observed that entry point distance from the midline varies with physical parameters of the patient (►Fig. 3), therefore the purpose of our study is to evaluate “effect of

physical parameters on the different entry points” in TELD in lower lumbar discs. We found statistically significant (p -value < 0.0001) increase in “distance from midline” of all five entry points, i.e., 45-45, PL, PL-TOSP, TOSP, and DFJ with physical parameters like weight, BMI and abdominal girth, hence one static figure for all the patients cannot be used. We found variations in the angle of entry point trajectory with the physical parameters for all five entry points. Variations were least for PL-TOSP, whereas the variations were significant with PL and TOSP individually because of the difference in posterolaterally placed fat in the posterior abdominal wall with variable physical parameters.

Amongst all the five entry points, only PL-TOSP skin entry point was proportionately changing with physical parameters; hence prediction equation was calculated using linear regression and with only those variables with correlation coefficient more than 0.4 and a significant p -value (< 0.05). TOSP-PL length difference changes with BMI in such a way that TOSP entry point shifts medially to PL entry point for BMI less than 18.55 ($p = 0.117$), where the prediction equation may not work.

In contrast to the fixed PL entry point proposed in various studies, we found that PL-TOSP entry was safe and accurate to access the central, paracentral herniations, and lateral canal stenosis. Using that entry point, directly visualized decompression of the targeted nerve root could be achieved in all

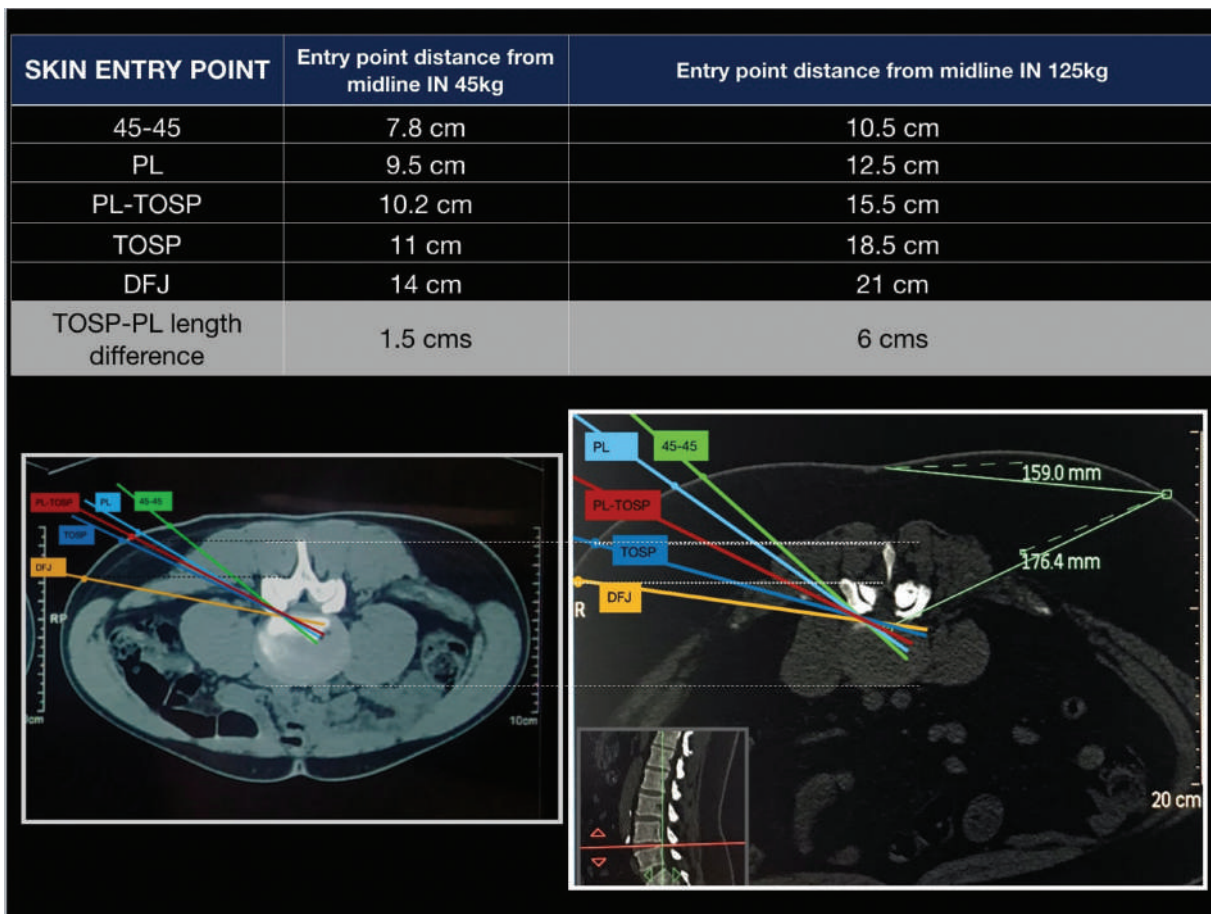


Fig. 3 Shows field of vision (FOV) view of CT scan . All four entry points, i.e., 45-45, PL, TOSP, and DFJ distance from midline increase with weight.

the cases without wide annulotomy or foraminotomy, however, further multicenter trials are required validating the above observation. On the other hand, PL-TOSP entry can prevent possible complications of far lateral entry points,^{15,25} i.e., dysesthesia due to exiting nerve root injury and bowel injury.

We found very few complications like recurrences (4.02%), dysesthesia (1.72%), and revision surgery (1.14%). No discitis, motor weakness, and dural tear were reported in our study. The overall VAS score decreased from a preoperative value of 7.98 to 1.84 at 6 months follow-up (p -value < 0.05), and the overall ODI improved from 72.53 to 16.26 (p -value < 0.05).

One of the limitations of this study is that it's a single-center single surgeon trial with a relatively short follow-up. We propose further studies comparing PL-TOSP entry with other entry points for central, paracentral herniation, and lateral canal stenosis as it was beyond our research scope. A multicenter trial of the derived formula is required to validate the same.

Conclusion

The entry point in TELD is not a fixed value as it varies with the physical parameters like weight and the abdominal girth of the patient. The PL-TOSP entry point is another safe entry which could be predicted preoperatively and least affected with physical parameters for lower lumbar pathologies.

Conflict of Interest

None declared.

Authors' Contributions

P.P. contributed toward concept and design. P.P., V.G., U.A., and V.P. collected and assembled the data. P.P., V.G., and N.M. analyzed and interpreted the data. All authors wrote the manuscript and gave its final approval. Administrative support was given by none of the authors.

References

- Yeung AT. The evolution and advancement of endoscopic foraminal surgery: one surgeon's experience incorporating adjunctive technologies. *SAS J* 2007;1(03):108–117
- Kambin P, Savitz MH. Arthroscopic microdiscectomy: an alternative to open disc surgery. *Mt Sinai J Med* 2000;67(04):283–287
- Kambin PNASS. Arthroscopic microdiscectomy. *Spine J* 2003;3(Suppl 3):60S–64S
- Kambin P. Posterolateral percutaneous lumbar discectomy and decompression: arthroscopic microdiscectomy. In: *Arthroscopic Microdiscectomy Minimal Intervention in Spinal Surgery*. Baltimore, Maryland, and Munich, Germany: Urban & Schwarzenberg; 1991:67–99
- Yue JJ, Long W. Full endoscopic spinal surgery techniques: advancements, indications, and outcomes. *Int J Spine Surg* 2015;9:17
- Kapetanakis S, Gkasdaris G, Angoules AG, Givissis P. Transforaminal percutaneous endoscopic discectomy using transforaminal endoscopic spine system technique: pitfalls that a beginner should avoid. *World J Orthop* 2017;8(12):874–880
- Choi G, Lee SH, Bhanot A, Raiturker PP, Chae YS. Percutaneous endoscopic discectomy for extraforaminal lumbar disc herniations: extraforaminal targeted fragmentectomy technique using working channel endoscope. *Spine* 2007;32(02):E93–E99
- Choi G, Lee SH, Lokhande P, et al. Percutaneous endoscopic approach for highly migrated intracanal disc herniations by foraminoplasty technique using rigid working channel endoscope. *Spine* 2008;33(15):E508–E515
- Kambin P, Gellman H. Percutaneous lateral discectomy of the lumbar spine a preliminary report. *Clin Orthop Relat Res* 1983; (174):127–132
- Yeung AT. Minimally invasive disc surgery with the Yeung Endoscopic Spine System (YESS). *Surg Technol Int* 1999;8:267–277
- Yeung AT, Yeung CA. Advances in endoscopic disc and spine surgery: foraminal approach. *Surg Technol Int* 2003; 11:255–263
- Tsou PM, Alan Yeung C, Yeung AT. Posterolateral transforaminal selective endoscopic discectomy and thermal annuloplasty for chronic lumbar discogenic pain: a minimal access visualized intradiscal surgical procedure. *Spine J* 2004;4(05):564–573
- Gore S, Yeung A. The “inside out” transforaminal technique to treat lumbar spinal pain in an awake and aware patient under local anesthesia: results and a review of the literature. *Int J Spine Surg* 2014;8:28
- Ahn Y. Transforaminal percutaneous endoscopic lumbar discectomy: technical tips to prevent complications. *Expert Rev Med Devices* 2012;9(04):361–366
- Ruetten S, Komp M, Godolias G. An extreme lateral access for the surgery of lumbar disc herniations inside the spinal canal using the full-endoscopic uniportal transforaminal approach-technique and prospective results of 463 patients. *Spine* 2005;30(22):2570–2578
- Datar GP, Shinde AB, Bommakanti K. Technical consideration of transforaminal endoscopic spine surgery for central herniation. *Indian J Pain* 2017;31:86–93
- Yeung AT, Tsou PM. Posterolateral endoscopic excision for lumbar disc herniation: surgical technique, outcome, and complications in 307 consecutive cases. *Spine* 2002;27(07):722–731
- Osman SG, Marsolais EB. Endoscopic transiliac approach to L5-S1 disc and foramen. A cadaver study. *Spine* 1997;22(11):1259–1263
- Patgaonkar P, Datar G, Agrawal U, et al. Suprailiac versus transiliac approach in transforaminal endoscopic discectomy at L5-S1: a new surgical classification of L5-iliac crest relationship and guidelines for approach. *J Spine Surg* 2020;6(Suppl 1):S145–S154
- Choi K-C, Lee DC, Park C-K. Modified endoscopic access for migrated and foraminal/extraforaminal disc herniation. In: Kim J-S, Lee JH, Ahn Y, eds. *Endoscopic Procedures on the Spine*. Singapore: Springer Singapore; 2020:159–173
- Krzok G. Transpedicular endoscopic surgery for highly down-migrated L5-S1 disc herniation. *Case Rep Med* 2019; 2019:5724342
- Hoogland T. Transforaminal endoscopic discectomy with formi-noplasty for lumbar disc herniation. *Surg Tech Orthop* 2003;1–6
- Lee JH, Jeon GR, Ro JH, Byoen GJ, Kim TK, Kim KH. Evaluation of an experimentally designed stereotactic guidance system for determining needle entry point during uniplanar fluoroscopy-guided intervention. *Korean J Pain* 2012;25(02):81–88
- Ahn SS, Kim SH, Kim DW. Learning curve of percutaneous endoscopic lumbar discectomy based on the period (early vs. late) and technique (in-and-out vs. in-and-out-and-in): a retrospective comparative study. *J Korean Neurosurg Soc* 2015;58(06): 539–546
- Kim HS, Sharma SB, Wu PH, et al. Complications and limitations of endoscopic spine surgery and percutaneous instrumentation. *Indian Spine J* 2020;3:78–85